



**PATIENT**

Cobble Brubaker

**PRESENTING CLINICAL SIGNS**

History: Recheck echo. Grade 3-4/6 heart murmur. Doing well Assess prior to dental.  
-Pertinent previous echo findings (6/2022 MML): Mild MR, mild PAH: 3.0m/s. LA: 1.4, LV: 1.7.

**SPECIES**

Canine

**ECHOCARDIOGRAM FINDINGS**

2D, m-mode, color flow and doppler imaging is available. Mild diffuse thickening of mitral valve leaflets with minimal prolapse into the left atrial lumen. Trace mitral regurgitation with minimal left atrial dilation. Normal LV diameter with adequate myocardial function. The tricuspid valve appears normal with mild tricuspid regurgitation. Velocity consistent with early pulmonary hypertension. Normal right heart. The pulmonic and aortic valves are normal in morphology and mobility. Normal pulmonic and aortic outflow velocities with laminar flow. No obvious aortic or pulmonic insufficiency. No pericardial or pleural effusion noted. No obvious cardiac masses.

**BREED**

Chihuahua

**SEX**

Female Spayed

**CARDIAC CHART**

**AGE**

14 years

**WEIGHT**

5.6lbs

**INTERPRETED BY**

Maggie Machen Lamy,  
DVM, DACVIM  
(Cardiology)

CANINE CARDIAC PARAMETERS	MR VMAX (m/s)	TR VMAX (m/s)	LA/AO (Boon method)	LA/AO (Heart Base; Swe)	FS (%)	EF (%)	EPSS (cm)
NORMAL PARAMETER	4.5-5.5	<2.7	1.3	<1.6	28-40	40-100	<0.6
PATIENT	NM	3.2	NM	1.4	44.	80	NM
CANINE CARDIAC PARAMETERS	HR (BPM)	AV VMAX (m/s)	PV MAX (m/s)	BODY WEIGHT (kg)	LA 2D short axis Base view (cm)	LVIDd Avg; 2D and m-mode short axis (cm)	LVIDs Avg; 2D and m-mode short axis (cm)
NORMAL PARAMETER	50-100	0.7-1.7	0.7-1.6	BELOW	BELOW	BELOW	BELOW
PATIENT	NM	0.9	1.0	2.5	1.4	1.6	0.9
*Normal chamber parameters expressed as a mean value (SD)				3	1.27 (5.3)	2.46 (2.46)	1.36 (5.5)
<b>BODY WEIGHT DEPENDENT PARAMETERS</b>				5	1.40 (4.5)	2.74 (5.2)	1.60 (4.7)
<i>*Note: All measurements based upon multi-modal images and methods. An average value is reported.</i>				10	1.50 (3.8)	3.27 (3.5)	2.06 (3.1)
				15	1.83 (2.0)	3.71 (2.4)	2.43 (2.1)
				20	2.02 (1.9)	4.14 (2.2)	2.80 (2.0)
				25	2.18 (2.4)	4.48 (2.9)	3.10 (2.5)
				30	2.33 (3.3)	4.83 (3.9)	3.39 (3.4)
				35	2.48 (4.3)	5.17 (5.0)	3.69 (4.5)
				40	2.62 (5.2)	5.48 (6.1)	3.96 (5.4)
				50	2.88 (7.1)	6.07 (8.3)	4.46 (7.4)

**INTERPRETATION OF THE FINDINGS & FURTHER RECOMMENDATIONS**

Chronic degenerative valve disease causing trace/mild mitral and tricuspid regurgitation persists. Compared to the prior study, findings are similar. No progression in left heart dimensions is identified and the pulmonary hypertension is unchanged.

**INVOICE**

30013

Given these findings, no cardiac medications are indicated. Assessment of progression in the future will help predict long term prognosis, which is highly variable at this stage. Omega fatty acid supplementation and mild salt restriction may be of some long-term benefit. Monitor for development of a cough, labored breathing, exercise intolerance or collapse episodes.

**DATE**

4/3/23

**REFERRING VET**

Dr. Kelly

**HOSPITAL NAME**

Round Hill Animal Hospital

Loetitia St-Jacques,  
LVT/RVT

**IMAGING PERFORMED BY**



**PATIENT**

Cobble Brubaker

**SPECIES**

Canine

**BREED**

Chihuahua

**SEX**

Female Spayed

**AGE**

14 years

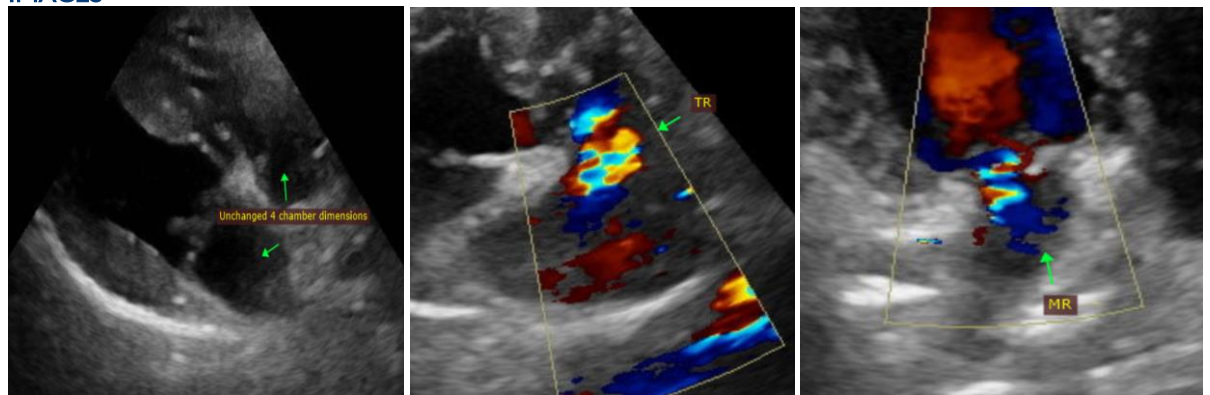
**WEIGHT**

5.6lbs

Anesthetic risk is considered mild if needed. Cardiac protective drug choices (opioid/benzodiazepine premedication, propofol or alfaxalone induction, isoflurane gas) are recommended. Pre-oxygenate for 5-10 minutes prior to induction. Monitor for arrhythmias, hypotension, and hypoxia both intra and post-operatively and intervene as necessary. Mild IV fluid restriction is recommended to avoid fluid overload. Avoid heart rate stimulating drugs such as atropine unless clinically indicated.

Recommend conservative monitoring with a recheck echocardiogram in 6-12 months, sooner if any development of clinical signs.

**IMAGES**



**INTERPRETED BY**

Maggie Machen Lamy,  
DVM, DACVIM  
(Cardiology)

The information and recommendations provided are based on the images presented by the referring veterinarian. No evaluation can be communicated regarding pathology that was not visible in the image/video clips provided.

Thank you for this referral. This report was generated using transcription software, and minor dictation errors may be present. If the clinical or image interpretation does not parallel your findings or if I can be of any further assistance, please contact me.

**IMAGING PERFORMED BY**

Loetitia St-Jacques,  
LVT/RVT

**Maggie Machen Lamy, DVM**  
Diplomate of the American College of Veterinary Internal Medicine (Cardiology)  
info@sonopath.com

**HOSPITAL NAME**

Round Hill Animal  
Hospital

**REFERRING VET**

Dr. Kelly

**INVOICE**

30013

**DATE**

4/3/23